Idiopathic Nonspecific Interstitial Pneumonia

Report of an American Thoracic Society Project

William D. Travis[1]*, Gary Hunninghake[2]*, Talmadge E. King, Jr.[3]*, David A. Lynch[4]*, Thomas V. Colby[5]*, Jeffrey R. Galvin[6]*, Kevin K. Brown[7], Man Pyo Chung[8], Jean-François Cordier[9], Roland M. du Bois[10], Kevin R. Flaherty[11], Teri J. Franks[12], David M. Hansell[13], Thomas E. Hartman[14], Ella A. Kazerooni[15], Dong Soon Kim[16], Masanori Kitaichi[17], Takashi Koyama[18], Fernando J. Martinez[11], Sonoko Nagai[19], David E. Midthun[20], Nestor L. Müller[21], Andrew G. Nicholson[22], Ganesh Raghu[23], Moisés Selman[24], and Athol Wells[10]

[1]Department of Pathology, Memorial Sloan Kettering Cancer Center, New York, New York; [2]Department of Medicine, University of Iowa, Iowa City, Iowa; [3]Department of Medicine, University of California, San Francisco, San Francisco, California; [4]Department of Radiology, National Jewish Medical and Research Center, Denver, Colorado; [5]Department of Pathology, Mayo Clinic, Scottsdale, Arizona; [6]Department of Radiology, University of Maryland, Baltimore, Maryland; [7]Department of Pulmonary Medicine, National Jewish Medical Research Center, Denver, Colorado; [8]Division of Pulmonary and Critical Care Medicine, Samsung Medical Center, Sungkyunkwan University School of Medicine, Seoul, Korea; [9]Service de Broncho-Pneumologie, Hôpital Cardiovasculaire et Pneumologique, Lyon, France; [10]Department of Pulmonary Medicine, Royal Brompton Hospital, London, United Kingdom; [11]Department of Pulmonary Medicine, University of Michigan, Ann Arbor, Michigan; [12]Department of Pulmonary and Mediastinal Pathology, Armed Forces Institute of Pathology, Washington, DC; [13]Department of Radiology, Royal Brompton Hospital, London, United Kingdom; [14]Department of Radiology, Mayo Clinic, Rochester, Minnesota; [15]Department of Radiology, University of Michigan, Ann Arbor, Michigan; [16]Department of Pulmonary Medicine, Asan Medical Center, Ulsan University, Seoul, Korea; [17]Laboratory of Anatomic Pathology, National Hospital Organization Kinki-chuo Chest Medical Center, Osaka, Japan; [18]Department of Radiology, and [19]Department of Respiratory Medicine, Graduate School of Medicine, Kyoto University, Kyoto, Japan; [20]Pulmonary Division, Mayo Clinic, Rochester, Minnesota; [21]Department of Radiology, University of British Columbia, Vancouver, Canada; [22]Department of Pathology, Royal Brompton Hospital, London, United Kingdom; [23]Pulmonary and Critical Care, University of Washington Medical Center, Seattle, Washington; and [24]Instituto Nacional de Enfermedades Respiratorias, Mexico City, Mexico

***Rationale*: The 2002 American Thoracic Society/European Respiratory Society classification of idiopathic interstitial pneumonias identified nonspecific interstitial pneumonia (NSIP) as a provisional diagnosis. Concern was expressed that NSIP was a "wastebasket" category, difficult to distinguish from other idiopathic interstitial pneumonias.**
***Objectives*: The following questions were addressed: (*1*) Is idiopathic NSIP a distinct entity? 2) If so, what are its clinical, radiologic and pathologic characteristics? (*3*) What is the role of radiology and pathology in establishing the diagnosis? (*4*) To make a diagnosis of idiopathic NSIP, what other disorders need to be excluded and how should this be done?**
***Methods*: Investigators who had previously reported cases of idiopathic NSIP were invited to submit cases for review (n = 305). After initial review, cases with complete clinical, radiologic, and pathologic information (n = 193) were reviewed in a series of workshops.**
***Measurements and Main Results*: Sixty-seven cases were identified as NSIP. Mean age was 52 years, 67% were women, 69% were never-smokers, and 46% were from Asian countries. The most common symptoms were dyspnea (96%) and cough (87%); 69% had restriction. By high-resolution computed tomography, the lower lung zones were predominantly involved in 92% of cases; 46% had a peripheral distribution; 47% were diffuse. Most showed a reticular pattern (87%) with traction bronchiectasis (82%) and volume loss (77%). Lung biopsies showed uniform thickening of alveolar walls with a spectrum of cellular to fibrosing patterns. Five-year survival was 82.3%.**
***Conclusions*: Idiopathic NSIP is a distinct clinical entity that occurs mostly in middle-aged women who are never-smokers. The prognosis of NSIP is very good.**

Keywords: high-resolution computed tomography scan; usual interstitial pneumonia; pathology; hypersensitivity pneumonitis; lung biopsy

AT A GLANCE COMMENTARY

Scientific Knowledge on the Subject

Nonspecific interstitial pneumonia was accepted by the 2002 American Thoracic Society/European Respiratory Society classification of idiopathic interstitial pneumonias, but it was regarded as "provisional," pending further study.

What This Study Adds to the Field

Idiopathic nonspecific interstitial pneumonia is a distinct form of idiopathic interstitial pneumonia. The diagnosis requires a dynamic integrated multidisciplinary approach because the histologic pattern can be seen in other disorders, such as hypersensitivity pneumonitis.

The 2002 American Thoracic Society (ATS) and the European Respiratory Society (ERS) International Consensus Panel for the Classification of Interstitial Lung Disease identified nonspecific interstitial pneumonia (NSIP) as a provisional diagnosis (1). Concern was expressed that NSIP (as currently defined) was a "wastebasket" category, difficult to distinguish from other idiopathic interstitial pneumonias (IIPs). Review of existing publications led the panel to conclude that there was a need to achieve a better consensus about the diagnosis of idiopathic NSIP and that additional study was required to determine if it was a distinct entity (1).

The initial rationale for the NSIP category was to recognize a group of patients with interstitial pneumonia that could not be classified as one of the other major IIPs (1). As the name implies, there are many "nonspecific" features from a clinical, radiologic, and pathologic view. In particular, the histopathologic pattern of NSIP could be found in a wide variety of clinical contexts, including diseases of known cause (e.g., hypersensitivity pneumonitis) as well as in the setting of an IIP. Concern was expressed that NSIP (as originally defined) was often

(*Received in original form November 22, 2006; accepted in final form April 3, 2008*)

Supported by the American Thoracic Society and European Respiratory Society.

*Members of the writing committee.

Correspondence and requests for reprints should be addressed to William D. Travis, M.D., Attending Thoracic Pathologist, Department of Pathology, Memorial Sloan Kettering Cancer Center, 1275 York Avenue, New York, NY 10065. E-mail: travisw@mskcc.org

Am J Respir Crit Care Med Vol 177. pp 1338–1347, 2008
Originally Published in Press as DOI: 10.1164/rccm.200611-1685OC on April 3, 2008
Internet address: www.atsjournals.org

difficult to distinguish from usual interstitial pneumonia (UIP) in the setting of idiopathic pulmonary fibrosis (IPF) (2–8). Growing data suggested this was not simply an academic or semantic argument, because UIP/IPF was shown to carry a far worse prognosis than idiopathic NSIP in studies where this distinction was attempted (2, 6–9). Consequently, this differentiation carried important clinical implications regarding patient outcome and choice of therapy. Furthermore, cellular and fibrosing patterns were recognized in idiopathic NSIP that carried prognostic differences, with a better survival associated with the cellular pattern (Table 2) (2–8).

Therefore, we formed a working group to answer the following questions:

1. Is idiopathic NSIP a distinct entity?
2. If so, what are its clinical, radiologic, and pathologic characteristics?
3. What is the role of radiology and pathology in establishing the diagnosis?
4. To make a diagnosis of idiopathic NSIP, what other disorders need to be excluded and how should this be done?

METHODS

Organization of the Working Group

The goal of this working group was to define the clinical, radiologic, and pathologic features of idiopathic NSIP based on a pooled dataset of cases with surgical lung biopsy, high-resolution chest computed tomography (HRCT), and clinical data. To develop a broad consensus on this complicated topic, an international panel of expert pathologists, clinicians, and radiologists was organized, including a core group who had participated in the 2002 ATS/ERS classification of IIPs (1). This project was sponsored by the ATS.

Approach to the Study

This study was accomplished through a series of multidisciplinary workshops as summarized in Table 1. A number of investigators who had previously reported cases of idiopathic NSIP were invited to participate in the workshop. Three hundred and five cases were submitted (*see below*). Throughout the workshop, the level of certainty for the diagnosis of idiopathic NSIP was defined as either definite, probable, possible, or definitely not, modeled after the approach used by the University of Michigan Interstitial Lung Disease group (9, 10). This reflected the confidence of pathologists, radiologists, or pulmonologists for or against the diagnosis of NSIP. "Definite" or "definitely not" were strong opinions for or against the diagnosis of NSIP, respectively. The levels of "probable" or "possible" were not as strong, but were opinions that either favored or did not favor the diagnosis of NSIP, respectively. A Kaplan-Meier survival curve was generated with the SPSS software program, version 13.0 (SPSS, Inc., Chicago, IL).

Inclusion and Exclusion Criteria

The starting point for the workshop was a pathologic diagnosis of NSIP as described in the ATS/ERS statement on IIPs (1) with the purpose of refining the definition of NSIP and sharpening the differential diagnosis.

Cases with established clinical, radiologic, or pathologic criteria that fit for other disorders, such as UIP, cryptogenic organizing pneumonia (COP), hypersensitivity pneumonitis, airway disease/bronchiolitis, respiratory bronchiolitis–interstitial lung disease (RB-ILD), desquamative interstitial pneumonia (DIP), or diffuse alveolar damage, were excluded. Cases that met rheumatologic criteria for collagen vascular disease or had exposure to drugs or airborne antigens known to cause lung disease at presentation were also excluded. However, patients who developed a collagen vascular disease after the initial diagnosis were included in the initial pool of cases.

Pathologic Review

The goal of the pathology review was to select cases in which there was a consensus diagnosis of NSIP among experts and to explore the histologic heterogeneity of NSIP. Surgical lung biopsies from the original 305 cases (Table 1) were reviewed by a panel of six pathologists (T.V.C., T.J.F., M.K., J.L.M., A.G.N., and W.D.T.), with each case reviewed by at least two pathologists. This initial review provided an overall pathologic assessment of the submitted lung biopsy material. The cases were reviewed without knowledge of the clinical or radiologic data and classified according to the ATS/ERS 2002 criteria (1). Level of certainty of the pathologic diagnosis and concern about possible differential diagnostic considerations were recorded.

Radiologic Review

The goals of the radiologic aspect of the project were as follows: (*1*) to develop a radiologic case definition of NSIP based on review of those cases accepted histologically; (*2*) to validate the case definition by review of biopsy-proven cases; and (*3*) to trigger focused pathologic rereview of cases with atypical features, or findings considered inconsistent with NSIP.

HRCT examinations were accepted for interpretation if they met the following criteria: 1- to 2-mm slice thickness, scans performed on third-generation scanners or later model scanners. HRCTs were digitized and sent to participating radiologists on compact discs. The CT scans were independently reviewed by a panel of six radiologists (D.A.L., J.R.G., D.M.H., N.L.M., T.E.H., and E.A.K.) on lung windows only, with each case reviewed by three of the six radiologists. The interpreters systematically scored each HRCT for the presence,

TABLE 1. REVIEW PROCESS FOR SELECTION OF FINAL 67 NONSPECIFIC INTERSTITIAL PNEUMONIA CASES

I. Review of 305 Cases with 193 Cases Selected for Further Evaluation
1. July 2001: Initial pathologic review of 305 cases
   (i) Six pathologists and two pulmonologists
2. September–December 2001: Initial CT review of 305 cases
   (i) Each case reviewed by three of six radiologists

II. Multidisciplinary Iterative Review of 193 Selected Cases and Detailed Radiologic Review with Selection of 67 Definite or Probable NSIP Cases
1. December 2001: Interactive workshop using a dynamic integrated approach with clinical-radiologic-pathologic review of 63 of the 193 cases
   (i) Six pathologists, 11 pulmonologists, and three radiologists
2. January–June 2002: Detailed NSIP CT data. Each case reviewed by three of six radiologists
3. June 2002: Interactive workshop using a dynamic integrated approach with clinical-radiologic-pathologic review of remaining 130 of the 193 cases
   (i) Seven pathologists, 12 pulmonologists, three radiologists

III. Detailed Clinical, Radiologic, and Pathologic Review of the Selected 67 NSIP Cases, Data Analysis, and Manuscript Preparation
1. December 2002: Interactive workshop using a dynamic integrated approach with clinical-radiologic-pathologic review of final 67 NSIP cases
   (i) Three pathologists, two pulmonologists, two radiologists
2. February 2003: Detailed review of pathology data from 67 definite and probable NSIP cases
   (i) Three pathologists
3. May 2003: Report of the ATS Workshop on Idiopathic Nonspecific Interstitial Pneumonia, symposium presentation at the ATS meeting, Seattle, Washington
4. May 2006: Writing committee meeting: final summary for this manuscript

Definition of abbreviations: ATS = American Thoracic Society; CT = computed tomography; NSIP = nonspecific interstitial pneumonia.

extent, and distribution of reticular abnormality, traction bronchiectasis, ground-glass attenuation, micronodules, and honeycombing, without knowledge of the clinical or pathologic data. Three radiologists (D.A.L., J.R.G., and T.E.K.) participated in the initial multidisciplinary review. After this review, scans were rescored by the same panel of six radiologists for evaluation of additional features (mixed ground-glass/reticular abnormality, subpleural sparing, lobar volume loss, cysts, perilobular thickening), for the presence of patterns suggestive of NSIP, and for the degree of diagnosis certainty for NSIP, based on the working radiologic definition. Two radiologists (D.A.L. and J.R.G.) participated in the June and December 2002 workshops.

Among the final 67 cases of idiopathic NSIP, all HRCTs were regarded as having sufficient certainty about the clinical-radiologic-pathologic (CRP) diagnosis of NSIP; however, in 6 cases the HRCT images were not of sufficient quality for a detailed review of all the aforementioned HRCT features; these are excluded from the summary data.

Clinical Review

The pulmonologists reviewed the clinical findings, including presenting symptoms, pulmonary function tests, serologies, and exposure histories. In addition, they reviewed the HRCT examinations before hearing the radiologist's interpretations, and their opinion was recorded for each case with level of certainty score regarding the diagnosis of NSIP.

Clinical-Radiologic-Pathologic Review

Each case was discussed at a multidisciplinary review in which the clinical findings, HRCT results, and lung biopsy features were discussed together in the context of the opinions rendered independently by the pathologists, radiologists, and pulmonologists (Table 1). At the time of this review, the HRCT scans, lung biopsy, and clinical history were re-reviewed, presented to the group, and a new consensus CRP opinion was rendered for the diagnosis of NSIP for each case with a level of certainty score; differential diagnostic concerns were also recorded. During this process, the dynamic integrated approach was applied as recommended in the 2002 ATS/ERS classification of IIPs (1). As a result, individual clinical, radiologic, or pathologic opinions could be overruled by data gathered from the consensus review.

Literature Review

Relevant articles from the medical literature were identified by a MEDLINE search of English language articles or articles with English abstracts, the bibliographies of the articles retrieved, and review of the committee members' files. The clinical, radiologic, and pathologic features of the major published articles on the topic of NSIP were reviewed (Table 2).

RESULTS

Of the original 305 cases, 112 were excluded if the submitted lung biopsy, HRCT examination, or clinical history were inadequate, incomplete, or contradictory. A total of 193 had clinical, radiologic, and pathologic materials acceptable for inclusion in the study. Sixty-seven of these cases were identified as definite (n = 17) or probable (n = 50) NSIP. The final diagnosis in the 67 cases was established when (*1*) the surgical lung biopsy showed a NSIP pattern (cellular or fibrosing); (*2*) the HRCT showed a pattern consistent with NSIP and not diagnostic of other entities such as UIP or chronic hypersensitivity pneumonitis; and (*3*) there were no clinical features of another chronic ILD, such as collagen vascular disease, drug, or inhaled antigen exposure at the time of diagnosis.

Clinical, Radiologic, and Pathologic Experts' Confidence Level for Diagnosis of NSIP

Before the final consensus diagnosis, each participant was asked to provide his or her opinion as to the most likely diagnosis and a confidence level for that diagnosis (definite, probable, possible, or definitely not). Described below is the interpretation for each group (pathologists, radiologists, and clinicians) before the final multidisciplinary consensus diagnosis.

CRP definite NSIP. For the 17 cases of CRP definite NSIP, the pathology interpretation was definite NSIP in 14 and

TABLE 2. CLINICAL FEATURES OF MAJOR STUDIES OF NSIP

First Author (reference)	NSIP Pattern	No. of Pts	Age Mean, yr (range)	Sex (% *men*)	Dyspnea (%)	Cough (%)	Duration of Symptoms, yr (range)	5-yr Survival	Smoking History (%)		
									Current	Never	Ex
Katzenstein (5)	Overall	64	56 (9–78)	41	80		NA	11% dead*	NA	NA	NA
	Group 1	31	44 (9–70)	42	81	33	NA	No deaths*	NA	NA	NA
	Group 2	24	49 (11–71)	33	75	35	NA	15% dead*	NA	NA	NA
	Group 3	9	50 (16–78)	60	79	33	NA	33% dead*	NA	NA	NA
Bjoraker (2)	Overall	14	57 (40–73)	57	79	22	1.3 (±1.9)†	70	7	43	50
Cottin (3)	Overall	12	52 (31–68)	50	100	87	3.6 (1–164)	No deaths	17	50	33
Nagai (21)	Overall	31	58 (NA)	48	100	67	0.16 (0.02–2.6)	6% dead*	42	42	16
	Cellular	16	58 (NA)	38	100	100	NA	No deaths	38	50	13
	Fibrosing	15	58 (NA)	53	100	100	NA	12% dead*	46	33	20
Daniil (4)	Overall	15	43 (31–66)	47	100	100	1.5 (0.6–7.0)	80	60	40	NA
Travis (7)	Overall	29	47 (26–71)	69	NA	NA	NA	NA	67	NA	NA
	Cellular	7	39 (26–50)	71	NA	NA	NA	100	60	NA	NA
	Fibrosing	22	50 (30–71)	68	NA	NA	NA	90	68	NA	NA
Nicholson (6)	Overall	28	54 (±9.5)†	71	NA	NA	0.92 (0–15)	61	64	32	4
	Cellular	3	NA	NA	NA	NA	NA	100	NA	NA	NA
	Fibrosing	25	NA	NA	NA	NA	NA	45	NA	NA	NA
Flaherty (8)	Cellular	5	50 (±9)†	60	NA	NA	1.8 ± 2.0†	No deaths	40	NA	NA
	Fibrosing	28	56 (±11)†	57	NA	NA	2.2 ± 3.4†	85‡	71	NA	NA
Johkoh (19)		55	55 (30–71)†	29	NA	NA	NA	NA	NA	NA	NA
Monaghan (16)		31	49 (±9.6)†	65	NA	NA	2.4 ± 2.3†	75	23	35	42
Elliot (30)		26	50 (±12)†	64	NA	NA	2.4 ± 1.3†	NA	NA	NA	NA
Jegal (17)	Overall	48	55 (±11)†	30	NA	NA	5.4 ± 6.3†	NA	10	75	13
	Cellular	7	59 (±10)†	43	NA	NA	4.0 ± 3.9†	100	14	43	43
	Fibrosing	41	54 (±11)†	29	NA	NA	5.5 ± 7.0†	76.2	12	80	7

Definition of abbreviations: NA = not available; NSIP = nonspecific interstitial pneumonia; Pts = patients.

* Not 5-year survival, but % dead.

† SD or SEM.

‡ Survival for all patients with NSIP (cellular and fibrosing patterns).

probable NSIP in 3 cases, whereas the radiology interpretation was definite NSIP in 11, probable NSIP in 5, and possible NSIP in 1 case. For the pulmonologists, a diagnosis of definite NSIP was made in 11 cases and probable NSIP in 6 cases. In six cases, there was a unanimous reading of definite NSIP by pathologists, radiologists, and pulmonologists.

CRP probable NSIP. For the 50 cases of CRP probable NSIP, the pathology interpretation was definite NSIP in 11 cases and probable NSIP in 39. The radiology interpretation was definite NSIP in 10 cases, probable NSIP in 25, possible NSIP in 13, and definitely not NSIP in 2 cases. For the pulmonologists, there were 11 cases of definite NSIP, 31 cases of probable NSIP, 7 cases of possible NSIP, and 1 case of definitely not NSIP.

Review of the Consensus Cases of Definite or Probable NSIP

Clinical features. The clinical features of the 67 patients are summarized in Table 3. Follow-up in 66 patients ranged from 0.6 to 19.44 years with a mean of 4.3 years. Eight patients with NSIP died—seven patients died of NSIP, one died of a non-respiratory cause—and one underwent a lung transplant. At the time of last follow-up, 58 patients were alive with disease. Two patients subsequently manifested collagen vascular diseases (1 scleroderma and 1 polymyositis). Of the eight patients who died, seven had a fibrosing pattern of NSIP and one had a cellular pattern of NSIP. The 5-year survival was 82.3% and the 10-year survival was 73.2% (Figure 1). The 5-year survival for the NSIP cases was not significantly different from the 80.9% 5-year survival of the 126 patients who were excluded ($P > 0.05$). Clinical data regarding treatment were not available in most cases.

TABLE 3. CLINICAL FEATURES AT DIAGNOSIS OF 67 PATIENTS WITH IDIOPATHIC NONSPECIFIC INTERSTITIAL PNEUMONIA

Feature	Number (%)*
Age, yr	
Mean	52
Range	26–73
Sex	
Female	45 (67)
Male	22 (33)
Contributing institution	
Asian	31 (46)
Non-Asian	36 (54)
Symptoms	
Dyspnea (n = 67)	64 (96)
Duration dyspnea	
Median	7 mo
Range	1–120 mo
Cough (n = 67)	58 (87)
Duration cough	
Median	6 mo
Range	1–147 mo
Weight loss (n = 64)†	16 (25)
Fever (n = 64)†	14 (22)
Arthralgias (n = 64)†	9 (14)
Clubbing (N = 62)†	5 (8)
Raynauds (n = 63)†	5 (8)
Myalgias (n = 58)†	4 (7)
Skin rash (n = 64)†	3 (5)
Arthritis (n = 64)†	2 (3)
Serology	
Antinuclear antibody (n = 44)†	19 (43)
Rheumatoid factor (n = 44)†	10 (23)
Jo-1 (n = 14)†	0 (0)
Pulmonary function testing (n = 58)†	
Restrictive	46 (79)
Obstructive	2 (3)
Mixed	2 (3)
Normal	8 (14)
Smoking (n = 65)†	
Never	45 (69)
Former	16 (25)
Persistent	4 (6)
Pack-years (n = 19)†	
Mean	26
Range	1–96
Survival (n = 66)†	
5-yr	82.3%
10-yr	73.2%

* Values are number (%) unless otherwise indicated.
† n = the number of patients for whom data for this feature were available.

Pathologic features. An extensive review of the 67 definite or probable cases of NSIP was performed (T.V.C., T.J.F., and W.D.T.) to develop a detailed histologic assessment of NSIP, as summarized in Table 4. All surgical lung biopsies classified as NSIP showed features that met the 2002 ATS/ERS histologic criteria (1).

The histologic features of the NSIP pattern consisted of varying amounts of interstitial inflammation and fibrosis with a uniform appearance (Figures 2A–2D). Cases showing the cellular NSIP pattern demonstrated a mild to moderate interstitial chronic inflammatory infiltrate with little fibrosis (Figures 2A–2B). The fibrosing NSIP pattern consisted of interstitial thickening by uniform fibrosis of the same age usually preserving the alveolar architecture (Figures 2C–2D), with varying amounts of cellular inflammation. The observed frequencies of these patterns were cellular (n = 11, 16%) and fibrosing (n = 56, 84%). Honeycomb fibrosis was not seen, but areas of interstitial fibrosis with enlarged airspaces were seen in 58 (87%) cases. These enlarged spaces could be differentiated from honeycombing in that they lacked abundant dense, scarring fibrosis surrounding the airspaces and the lung architecture was generally preserved (Figures 2E–2F). In some cases, the abnormal airspaces appeared to represent dilated bronchioles with surrounding mild to moderate fibrosis causing traction bronchiolectasis or expansion of the airspaces (Figure 2F). In other cases, pseudo-stratified, ciliated bronchiolar epithelium was absent or inconspicuous (Figure 2E). Enlarged fibrotic airspaces were more common and more extensive in cases showing the fibrosing NSIP pattern than in cases with a cellular pattern.

Bronchiolocentricity of inflammation or fibrosis was seen in 9 (13.4%) cases; when present it was not a dominant feature. Organizing pneumonia involving less than 20% of the overall biopsy specimen was seen in 35 (52%) cases, and in 33 (49%) of these cases it was less than 10% of the specimen. Inconspicuous fibroblastic foci were seen in 14 (21%) of cases, and were only seen in cases of the fibrosing NSIP pattern.

Radiologic features. In 61 of the definite or probable NSIP cases, the HRCT images were adequate for detailed analysis (Table 5). The parenchymal abnormalities predominantly involved the lower lungs (92%) in the craniocaudal dimension, with 8% being equally severe in the upper and lower lungs.

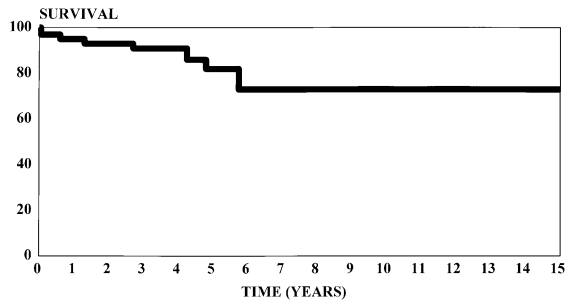

Figure 1. Survival in nonspecific interstitial pneumonia. Survival at 5 years was 82.3% and at 10 years was 73.2%.

TABLE 4. IDIOPATHIC NONSPECIFIC INTERSTITIAL PNEUMONIA: PATHOLOGIC FEATURES OF 67 CASES

Pathologic Feature	Number	Percentage	95 CI
NSIP pattern			
Cellular	11	16	9–27
Fibrosing	56	84	73–91
Bronchiolocentric (as a minor finding)	9	13	7–24
Lymphoid follicles	38	57	45–68
Interstitial fibrosis with enlarged airspaces*			
Absent	9	13	7–24
<10%	23	34	24–46
10–50	24	36	25–48
>50%	11	17	9–27
Interstitial cellular inflammation			
Mild	31	46	35–58
Moderate	36	54	42–65
Organizing pneumonia			
Absent	32	48	36–60
0–9%	33	49	38–61
10–19%	2	3	1–10
Smooth muscle hyperplasia	22	36	23–45
Fibroblastic foci	14	21	13–32
Bronchiolar metaplasia	13	19	12–30
Pleural fibrosis	37	55	43–67
Vascular medial thickening	43	64	52–75
Emphysema	4	6	2–14

Definition of abbreviations: CI = confidence interval; NSIP = nonspecific interstitial pneumonia.

* Distinct from honeycombing in cases of usual interstitial pneumonia; *see* text.

They were diffuse (58%) or had a predominantly peripheral (35%) distribution in the axial dimension. The most common HRCT features were a reticular pattern (87%), traction bronchiectasis (82%), and lobar volume loss (77%) (Figures 3A–3B). Ground-glass attenuation was present in nearly half of the cases (44%). Uncommon features included subpleural sparing (21%) and peribronchiolar thickening (6.6%). Honeycombing was seen in only three (4.9%) cases.

Review of the Consensus Cases Excluded from NSIP

The remaining 126 cases (including 80 possible and 46 definitely not NSIP) were excluded based on the multidisciplinary CRP consensus review. There was insufficient time for the panel members to carefully review and perform detailed analysis of all the 126 excluded cases. However, the panel chose to exclude three major groups of diagnoses because they were concerned about possible diagnoses of hypersensitivity pneumonitis (n = 59, 46.8%), UIP (n = 28, 22.2%), and organizing pneumonia (n = 23, 18.3%). The remaining cases were suspected to represent a miscellaneous group of less common disorders including the following: six (4.8%) RB, four (3.2%) diffuse alveolar damage, three (2.4%) fibrosing interstitial pneumonia not further classified, two (1.6%) airway disorders, and one (0.8%) DIP. Three patients with collagen vascular diseases (1 with rheumatoid arthritis, 2 with polymyositis) at the time of lung biopsy were excluded. (As the project evolved, it became apparent that some of the cases excluded by the CRP consensus review process were not regarded as NSIP by the referring centers and were deliberately submitted as "controls" to test the diagnostic criteria and differential diagnosis.)

Impact of HRCT or Clinical Data on Final Diagnosis of Cases with Pathologic Findings of Definite or Probable NSIP

The pathologic diagnosis of definite (n = 31) or probable (n = 74) NSIP was made in 104 cases. However, the findings on HRCT or clinical data resulted in a consensus diagnosis other than idiopathic NSIP in 38 (37%) cases. Alternative diagnoses were favored by HRCT alone in 21 (20%) cases, clinical data and HRCT in 14 (14%) cases, and clinical data alone in 2 (2%) cases (e.g., due to a history of exposure to birds).

A consensus CRP diagnosis other than idiopathic NSIP was found in 6 of 31 cases (19%) with a pathologic diagnosis of definite NSIP. Alternative diagnoses were favored by HRCT alone in 4 (13%) cases, by clinical review in 1 (3%) case, and by both clinical and CT data in 1 (3%) case. In these six cases, the review favored hypersensitivity pneumonitis in three cases (10%), COP in two cases (6%), and airway disease in one case (3%).

Of a total of 73 cases in which a pathologic diagnosis of probable NSIP was made, a consensus diagnosis other than idiopathic NSIP was obtained in 32 cases (44%): 17 (25%) were based primarily on HRCT, 13 (18%) on clinical data and HRCT, and 2 (3%) primarily on clinical data (due to a history of exposure to birds). In these 32 cases, the review favored hypersensitivity pneumonitis in 18 cases (25%), organizing pneumonia in 9 cases (12%), UIP in 3 cases (4%), and fibrosing interstitial pneumonia not further classified in 2 cases (3%).

DISCUSSION

This multidisciplinary workshop showed that there is a consensus among experts that idiopathic NSIP is a distinct clinical entity with characteristic clinical, radiologic, and pathologic features that differ from other IIPs.

1. The clinical presentation is breathlessness and cough of usually 6 to 7 months' duration, predominantly in women, never-smokers, and in the sixth decade of life. Most patients have a restrictive ventilatory defect on lung function testing.
2. Key features on HRCT are bilateral, symmetric, predominantly lower lung reticular opacities with traction bronchiectasis and lower lobe volume loss that is usually diffuse or subpleural in the axial dimension, but sometimes spares the subpleural lung (Table 5).
3. The key histopathologic features of the NSIP pattern are the uniformity of interstitial involvement with a spectrum from a cellular to a fibrosing process (Tables 3 and 6).
4. The majority of patients with idiopathic NSIP have a good prognosis, with a 5-year mortality rate estimated at less than 18%.

Dynamic Integrated Approach Required for Accurate Diagnosis

We applied a dynamic integrated approach to the diagnosis as described in the 2002 ATS/ERS classification (1). During this process, the CRP consensus review commonly changed the individual opinions rendered by clinicians, radiologists, or pathologists. In individual cases, a consensus diagnosis of NSIP could not be achieved unless the CRP features were all compatible (i.e., definite or probable) with that diagnosis. When all the clinical, radiologic, and pathologic features are not definite or probable for NSIP, a multidisciplinary conference is especially advisable.

A consensus CRP diagnosis other than idiopathic NSIP was obtained in approximately one-third of cases in which a definite or probable pathologic diagnosis of NSIP was made. HRCT findings were the most common reason for driving a diagnosis other than idiopathic NSIP, followed by a combination of HRCT and clinical data. However, in a few cases, the clinical data were the primary reason, especially in patients with

a history of exposure to birds. In this workshop, it became apparent that when an HRCT scan shows classical features of hypersensitivity pneumonitis (11–15) or COP (1), these diagnoses are favored over idiopathic NSIP, even if a surgical lung biopsy shows histologic features of the NSIP pattern. Similarly, an HRCT showing a typical pattern of UIP (in particular, honeycomb changes) leads to a diagnosis of IPF, even when a surgical lung biopsy shows histologic features of NSIP (9, 16).

Clinical Features of Idiopathic NSIP

The NSIP patients studied in this workshop averaged 50 years of age, were mostly females and never-smokers, and often had positive serologies for collagen vascular disease. These findings are similar to those of previous reports, although there has been inconsistency about sex predilection, with some reporting male predominance (2, 6–8, 16), some female predominance (5, 17–20), and others an almost equal sex ratio (3, 4, 21). However, many of the published studies with a female predominance are from Asia and almost half of the patients with NSIP in our study are from Asian institutions and a significantly greater proportion of these patients were women. Therefore, the strong female predominance in our series may be in part due to the large contribution of Asian cases. The time of symptoms before diagnosis, sex distribution, smoking status, and survival rate suggest that idiopathic NSIP is a different entity from IPF/UIP. The available data regarding therapy were incomplete, making it difficult to present in this article.

Histologic Definition of the NSIP Pattern and Differential Diagnosis

The pathologic recognition of the NSIP pattern involves two major aspects: (*1*) recognition of the characteristic histologic features and (*2*) exclusion of other patterns of ILD.

Several modifications are proposed for the histologic definition of the NSIP pattern compared with that described in the ATS/ERS 2002 classification (Table 6) (1). Previously, Katzenstein and Fiorelli found focal organizing pneumonia affecting up to 10% of the biopsy in 39, 71, and 22% of cases of cellular, cellular and fibrosing, and fibrosing NSIP, respectively, with an overall frequency of 48% (5). We had an almost identical frequency of organizing pneumonia (46%), and the organizing

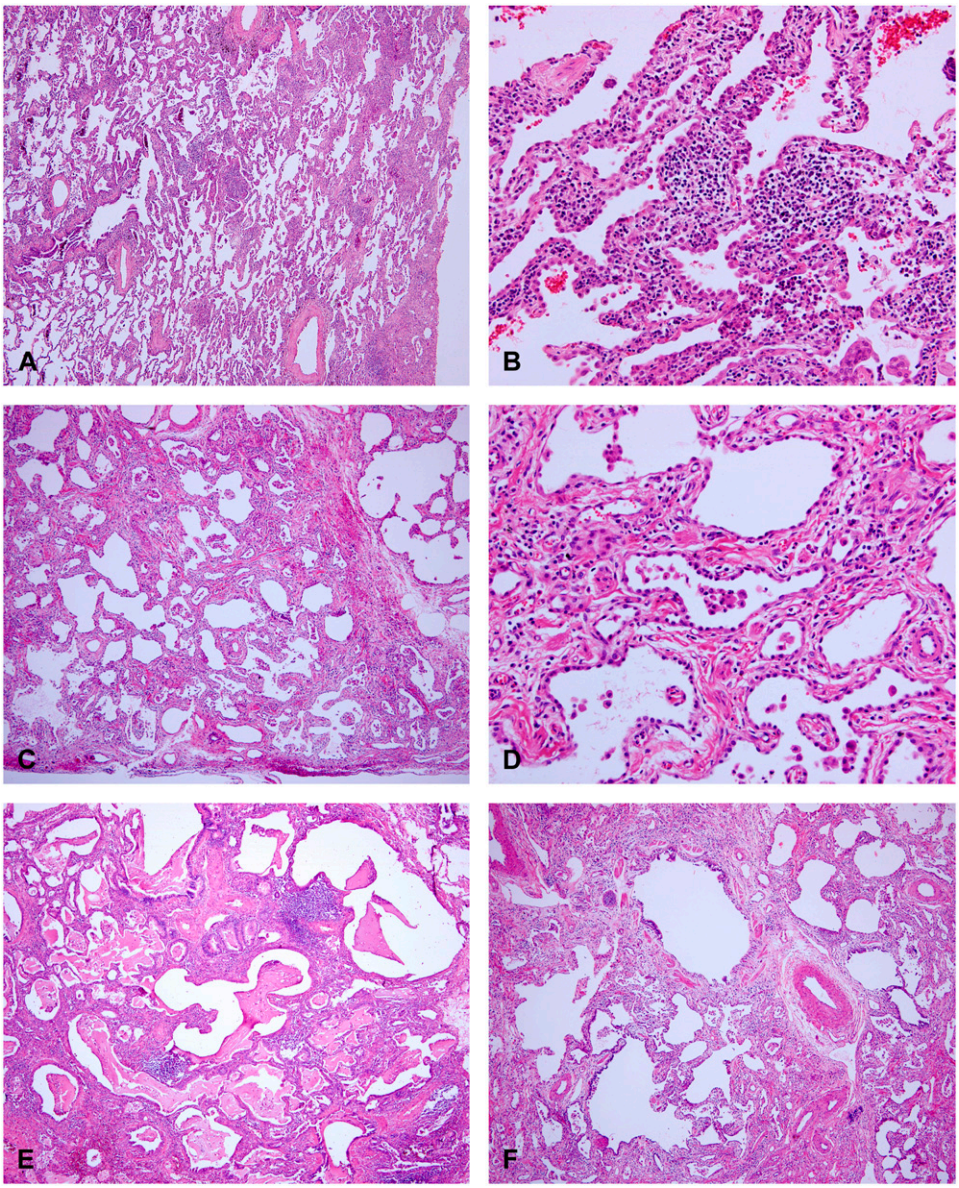

Figure 2. Pathology in nonspecific interstitial pneumonia. (*A*) Cellular pattern. The alveolar walls are thickened by a uniform, cellular, inflammatory interstitial infiltrate. The architecture of the lung is preserved. Small foci of organizing pneumonia are present. (*B*) Cellular pattern. The cellular infiltrate consists mostly of lymphocytes and a few plasma cells. (*C*) Fibrosing pattern. There is uniform thickening of the alveolar walls by interstitial fibrosis. The connective tissue appears to be the same age. No honeycombing or fibroblastic foci are seen. (*D*) Fibrosing pattern. The alveolar wall is thickened by dense interstitial fibrosis and a few chronic inflammatory cells. The overlying pneumocytes show cuboidal hyperplasia. A few alveolar macrophages are present. (*E*) Interstitial fibrosis with airspace enlargement. These airspaces are enlarged and surrounded by mild to moderate interstitial fibrosis. In contrast to the typical honeycombing of usual interstitial pneumonia, the lung architecture is generally preserved. Mucus is present within some of these airspaces. (*F*) Interstitial fibrosis with airspace enlargement. These bronchioles are dilated. The diameter of the larger bronchiole is approximately twice that of the adjacent muscular pulmonary artery, indicating traction bronchiolectasis. The surrounding alveolar walls are fibrotically thickened but the lung architecture is generally preserved.

TABLE 5. IDIOPATHIC NONSPECIFIC INTERSTITIAL PNEUMONIA: HIGH-RESOLUTION COMPUTED TOMOGRAPHY FEATURES IN 61 CASES

Radiologic Feature	Number (*n* = *61*)	Percent	95% CI
Craniocaudal Distribution			
Lower	56	92	82–96
Diffuse	5	8	4–18
Upper	0	0	0–6
CT axial distribution			
Diffuse	29	47	36–60
Peripheral	28	46	34–58
Central	4	7	3–16
Reticulation	53	87	76–93
Traction bronchiectasis	50	82	71–90
Lobar volume loss	47	77	65–86
Ground-glass attenuation	27	44	33–57
Subpleural sparing	13	21	13–33
Emphysema/cysts	7	12	6–22
Consolidation	8	13	7–24
Peribronchial thickening	4	7	3–16
Substantial micronodules	2	3	1–11
Honeycombing	3	5	2–13

Definition of abbreviations: CI = confidence interval; CT = computed tomography.

pneumonia pattern was less than 10% of the overall biopsy in most of our cases, but in two cases the amount was up to 20%, and after CRP correlation, it was concluded that the best final diagnosis was NSIP. The extent of histologic organizing pneumonia seems to show a continuum between the NSIP to organizing pneumonia patterns, and our decision to include a few cases with as much as 20% of the biopsy involved by organizing pneumonia is arbitrary.

The histologic differential diagnosis encountered during the course of the ATS NSIP workshop could have been predicted from the original description of NSIP by Katzenstein and Fiorelli (5). NSIP was defined by exclusion because it lacked features of the other three categories of IIP: UIP, DIP, and acute interstitial pneumonia (AIP) (5). This left room for a broad histologic spectrum. Katzenstein and Fiorelli included cases based solely on histologic features and thus cases with possible drug or collagen vascular disease association were included as were some cases that may have represented hypersensitivity pneumonitis. Not surprisingly, they recognized appreciable percentages of cases that showed bronchiolocentricity (28%), granulomas (8%), foci of organizing pneumonia (48%), DIP-like foci (30%), and fibroblast foci (20%) (5). During this workshop, lesions showing these features figured highly in the histologic differential diagnosis of NSIP, in that our CRP consensus review revealed diagnoses of hypersensitivity pneumonitis, organizing pneumonia, and UIP in cases in which lung biopsies showed a definite or probable NSIP pattern. New categories of differential diagnostic considerations that we observed included smoking-related lesions of DIP, RB-ILD, and emphysema (22–26), as well as small airway lesions (27–29).

Radiologic Features of Idiopathic NSIP

This workshop developed a consensus set of radiologic features for idiopathic NSIP based on this carefully characterized set of cases. Characteristic features include reticular opacities with lower lung zone predominance, associated with traction bronchiectasis and lobar volume loss. The distribution is predominantly diffuse or subpleural in the axial dimension. Although the abnormality shows peripheral predominance in about one-third of cases, the relative sparing of the immediate subpleural zone of lung seen in approximately 20% of our cases may sometimes be a helpful diagnostic finding. Ground-glass opacities are seen in about half of the cases. These findings are broadly consistent with previous studies, though the prevalence of consolidation and honeycombing is substantially less than that in some previous reports (Table 5) (18–20, 30–34). The most consistent finding in previous studies of NSIP was bilateral symmetric ground-glass opacities (18–20, 30–34). However, there have been widely varying reported percentages of consolidation, honeycombing, traction bronchiectasis, micronodules, and nodular opacities (18–20, 30–34).

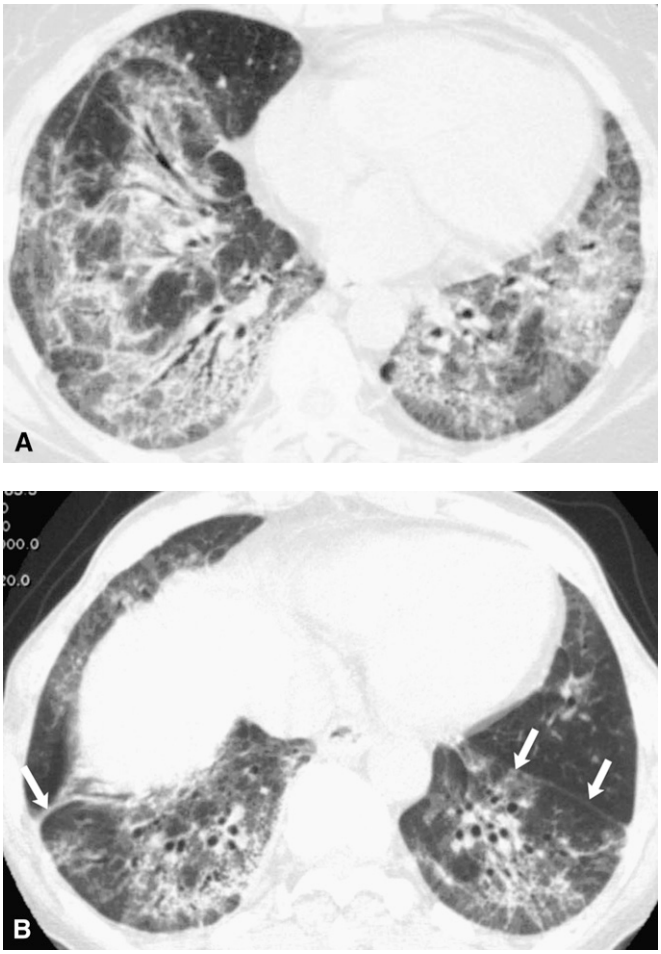

Figure 3. High-resolution computed tomography (HRCT) images in nonspecific interstitial pneumonia (NSIP). (*A*) HRCT through the lower lungs in a patient with NSIP shows confluent ground-glass/reticular abnormality and mild traction bronchiectasis. The abnormality extends along bronchovascular bundles in the right lower lobe, and spares the posterior subpleural lung. (*B*) HRCT through the lower lungs in a patient with NSIP shows confluent reticular abnormality and marked traction bronchiectasis. The abnormality extends along bronchovascular bundles in both lower lobes, and spares the posterior subpleural lung. There is posterior displacement of the interlobar fissures (*arrows*), indicating lobar volume loss.

The lower percentages of honeycombing and consolidation found in our study compared with previous reports probably reflect more stringent criteria for elimination of cases of UIP and COP. In particular, the presence of honeycombing on HRCT should raise a strong suspicion of UIP. With few exceptions (17), previous studies of NSIP have shown honeycombing on HRCT in minor percentages of patients. In this series, only 5% showed honeycombing on HRCT; none had histologic features to suggest UIP, and the overall HRCT features of

TABLE 6. PROPOSED REVISED HISTOLOGIC FEATURES OF NONSPECIFIC INTERSTITIAL PNEUMONIA

Key Features
Cellular Pattern*
Mild to moderate interstitial chronic inflammation
Type II pneumocyte hyperplasia in areas of inflammation
Fibrosing Pattern*
Dense or loose interstitial fibrosis *with uniform appearance.*
Lung architecture is frequently preserved
Interstitial chronic inflammation—mild or moderate
Pertinent Negative Findings
Cellular Pattern
Dense interstitial fibrosis: absent
Organizing pneumonia is not the prominent feature *(<20% of biopsy specimen)*
Lack of diffuse severe alveolar septal inflammation
Fibrosing Pattern
Temporal heterogeneity pattern: fibroblastic foci with dense fibrosis are inconspicuous or absent – this is especially important in cases with patchy involvement and subpleural or paraseptal distribution
Honeycombing inconspicuous or absent
(*Enlarged fibrotic airspaces may be present*)
Both Patterns
Acute lung injury pattern, especially hyaline membranes: absent
Eosinophils: inconspicuous or absent
Granulomas: *absent*
Lack of viral inclusions and organisms on special stains for organisms
Dominant airway disease such as extensive peribronchiolar metaplasia

Modifications from the 2002 American Thoracic Society/European Repiratory Society criteria for nonspecific interstitial pneumonia (NSIP) (1) are in italics. The key features are listed as a set of positive criteria, with all exclusions moved to a list of pertinent negative findings. It is emphasized that the dense or loose interstitial fibrosis should have a uniform appearance. The phrase "lacking the temporal heterogeneity pattern and/or patchy features of UIP" is deleted as this is mentioned in the "Pertinent negative findings" section. The phrase about lung architecture is modified to "Lung architecture is frequently preserved" and the statement about elastic stains is deleted. In the fibrosing NSIP section, "honeycombing inconspicuous or absent" is added. Under pertinent negatives for both patterns, "dominant airway disease such as extensive peribronchiolar metaplasia" is added. We changed the criteria about granulomas being inconspicuous or absent; so for idiopathic NSIP, granulomas should be absent.

* There is a spectrum from cellular to fibrosing patterns with some cases showing a combination of cellular and fibrosing features.

these cases were not suggestive of UIP. It is possible that our histologic finding of enlarged airspaces surrounded by interstitial fibrosis with relatively preserved lung architecture may correspond in some cases to the HRCT finding of traction bronchiectasis and bronchiolectasis. Historically, this lesion has probably been confused with the true honeycombing of UIP in which the architecture of the lung surrounding cystic spaces is destroyed by dense scarring fibrosis.

Prognosis of Idiopathic NSIP

The favorable survival in this series also corresponds to the observation in virtually all published studies of idiopathic NSIP. Although the outcome for NSIP is excellent compared with UIP, there is significant mortality, with almost 20% of patients being dead 5 years after diagnosis. At 10 years, the survival in our patients was 73.2%; we did not find the significant drop in survival between 5 and 10 years shown by several other studies (2, 6, 7). Several studies suggest that patients with the cellular NSIP pattern have a more favorable prognosis than those with the fibrosing NSIP pattern (6, 7). However, in this study, we had insufficient data to address this question. The survival in our patients with NSIP was similar to that of the patients who were excluded from this study, presumably because the non-NSIP group comprised a variety of conditions with differing prognoses, including hypersensitivity pneumonitis, UIP, and COP.

Heterogeneity of Conditions with a Pathologic NSIP Pattern

Another observation in this workshop was that the clinical, radiologic, and pathologic boundaries between idiopathic NSIP and a variety of other interstitial disorders are often blurred. The consensus among the group was that NSIP showed the most overlap clinically, radiologically, and histologically with the following: (*1*) hypersensitivity pneumonitis, (*2*) COP, (*3*) UIP/IPF, and (*4*) RB-ILD.

A growing number of reports have shown that NSIP is one of the most common patterns of interstitial pneumonia in patients with a variety of types of connective tissue disease, including scleroderma, rheumatoid arthritis, polymyositis/dermatomyositis, and Sjögren's syndrome (35–40). In some patients with connective tissue disease, ILD is the initial presenting manifestation (41), and this often takes the form of NSIP as was seen in two of our patients. It is possible that some cases of NSIP might be a pulmonary manifestation of an undifferentiated connective tissue disease. Infection and pulmonary drug toxicity may present pathologically in NSIP (42–44). NSIP can also be a manifestation of familial ILD (45–47). Also, the NSIP pattern may represent the sole or predominant morphology on surgical lung biopsy in a number of cases in which the CRP diagnosis is subacute or chronic hypersensitivity pneumonitis (48, 49).

Implications for Practice

We confirm that the histologic pattern of NSIP is encountered in patients who have a distinct form of IIP. We show that these patients have a distinct clinical presentation and disease course that is different from that reported for patients with UIP/IPF. However, the histologic pattern of NSIP is present in lung biopsies among a variety of clinical disorders, including collagen vascular disorders and hypersensitivity pneumonitis. In cases in which CT or biopsy are believed to show features of NSIP, but in which there are incomplete data or concern for an alternative diagnosis such as hypersensitivity pneumonitis, the term "NSIP pattern" is appropriate. Consequently, the diagnosis of idiopathic NSIP requires a dynamic integrated approach with input from clinicians, radiologists, and pathologists. The survival of patients with idiopathic NSIP is very good; however, additional studies are required to define the proper approach to treatment and long-term follow-up.

Future Work Needed for Study of NSIP

1. Study comparative clinical, radiologic, and pathologic features of idiopathic NSIP and (*1*) NSIP in known conditions such as connective tissue disease, (*2*) idiopathic pulmonary fibrosis, (*3*) hypersensitivity pneumonitis.
2. Define the incidence and prevalence of NSIP.
3. Determine if there is a sexual and ethnic predilection for NSIP.
4. Determine if idiopathic NSIP is an autoimmune disease.
5. Determine if NSIP associated with collagen vascular disease behaves differently or has different radiologic or pathologic features compared with idiopathic NSIP.
6. Initiate molecular and genetic studies comparing NSIP with the above conditions.
7. Clinical trials to identify optimal therapeutic agents.

Conflict of Interest Statement: W.D.T. does not have a financial relationship with a commercial entity that has an interest in the subject of this manuscript. G.H. does not have a financial relationship with a commercial entity that has an interest in the subject of this manuscript. T.E.K. does not have a financial relationship with a commercial entity that has an interest in the subject of this

manuscript. D.A.L. received <$5,000 in 2004, 2005, and 2006 from Intermune, Inc., for interpretation of CT scans in a clinical trial of idiopathic pulmonary fibrosis. He received <$5,000 from Encysive, Inc., for consultation. His institution, National Jewish and Medical Research Center, has a contract with Actelion, Inc., for interpretation of CT scans in clinical trials. T.V.C. does not have a financial relationship with a commercial entity that has an interest in the subject of this manuscript. J.R.G. does not have a financial relationship with a commercial entity that has an interest in the subject of this manuscript. K.K.B. does not have a financial relationship with a commercial entity that has an interest in the subject of this manuscript. M.P.C. does not have a financial relationship with a commercial entity that has an interest in the subject of this manuscript. J.-F.C. does not have a financial relationship with a commercial entity that has an interest in the subject of this manuscript. R.M.d.B. does not have a financial relationship with a commercial entity that has an interest in the subject of this manuscript. K.R.F. has served as a consultant for companies evaluating novel treatments for IPF including Genzyme, Intermune, and Boehringer Ingelheim. T.J.F. does not have a financial relationship with a commercial entity that has an interest in the subject of this manuscript. D.M.H. does not have a financial relationship with a commercial entity that has an interest in the subject of this manuscript. T.E.H. does not have a financial relationship with a commercial entity that has an interest in the subject of this manuscript. E.A.K. does not have a financial relationship with a commercial entity that has an interest in the subject of this manuscript. D.S.K. received $4,500 for consultation from Boehringer Ingelheim. M.K. does not have a financial relationship with a commercial entity that has an interest in the subject of this manuscript. T.K. does not have a financial relationship with a commercial entity that has an interest in the subject of this manuscript. F.J.M. does not have a financial relationship with a commercial entity that has an interest in the subject of this manuscript. S.N. does not have a financial relationship with a commercial entity that has an interest in the subject of this manuscript. D.E.M. does not have a financial relationship with a commercial entity that has an interest in the subject of this manuscript. N.L.M. has a GlaxoSmithKline-sponsored research grant on quantification of emphysema and airway abnormalities of CT scans in patients with COPD. The value of the grant over the last 3 years has been approximately $100,000/year. This grant is ongoing. He has served as a consultant for Actelion Pharmaceuticals and received $1,200. He has also consulted for Roche Pharmaceuticals but received no fees. A.G.N. received $2,500 in 2005–2007 and $5,350 in 2007 for reviewing slides in multicenter trials for Intermune Ltd, $18,850 in 2006 and $25,194 in 2007 for reviewing slides for a multicenter trial for Actelion Ltd, and $1,190 for lecturing on behalf of AstraZeneca in 2005 and 2006. G.R. does not have a financial relationship with a commercial entity that has an interest in the subject of this manuscript. M.S. does not have a financial relationship with a commercial entity that has an interest in the subject of this manuscript. A.W. does not have a financial relationship with a commercial entity that has an interest in the subject of this manuscript.

Acknowledgment: The authors gratefully acknowledge Jeffrey L. Myers, M.D., for his contribution in the initial phase and study design of this project. He is designated as J.L.M. in the initial pathologic review of the original 305 cases. Additional observers included the following: Michelle Freemer, M.D., Department of Medicine; University of California, San Francisco, San Francisco, California; Vincent Cottin, M.D., Lyon, France; Andrea Garrido Estrada, M.D., and Mayra Mejia, M.D., Instituto Nacional de Enfermedades Respiratorias, Mexico City, Mexico; Carlyne Cool, M.D., Department of Pathology, University of Colorado, Denver, Colorado; Rodney Schmidt, M.D., Department of Pathology, University of Washington, Seattle, Washington; Stephen Nishimura, M.D., Ph.D., Department of Pathology, University of California, San Francisco, San Francisco, California. The following pathologists are thanked for contributing pathology materials to this project: Joungho Han, M.D., Department of Pathology; Samsung Medical Center, Sungkyunkwan University School of Medicine, Seoul, Republic of Korea; Francoise Thivolet-Béjui, M.D., Ph.D., Hôpital Cardiovasculaire et Pneumologique, Lyon, France; Carlyne Cool, M.D., Department of Pathology, University of Colorado, Denver, Colorado; Rodney Schmidt, M.D., Department of Pathology, University of Washington, Seattle, Washington; Andrew Flint, M.D., Department of Pathology, University of Michigan, Ann Arbor, Michigan. Graham Nelan, Deputy Executive Director, Program & Development, of the American Thoracic Society is also gratefully acknowledged for his assistance with this project.

References

1. American Thoracic Society; European Respiratory Society. American Thoracic Society/European Respiratory Society international multidisciplinary consensus classification of the idiopathic interstitial pneumonias. *Am J Respir Crit Care Med* 2002;165:277–304.
2. Bjoraker JA, Ryu JH, Edwin MK, Myers JL, Tazelaar HD, Schroeder DR, Offord KP. Prognostic significance of histopathologic subsets in idiopathic pulmonary fibrosis. *Am J Respir Crit Care Med* 1998;157:199–203.
3. Cottin V, Donsbeck AV, Revel D, Loire R, Cordier JF. Nonspecific interstitial pneumonia. Individualization of a clinicopathologic entity in a series of 12 patients. *Am J Respir Crit Care Med* 1998;158:1286–1293.
4. Daniil ZD, Gilchrist FC, Nicholson AG, Hansell DM, Harris J, Colby TV, du Bois RM. A histologic pattern of nonspecific interstitial pneumonia is associated with a better prognosis than usual interstitial pneumonia in patients with cryptogenic fibrosing alveolitis. *Am J Respir Crit Care Med* 1999;160:899–905.
5. Katzenstein AL, Fiorelli RF. Nonspecific interstitial pneumonia/fibrosis: histologic features and clinical significance. *Am J Surg Pathol* 1994;18:136–147.
6. Nicholson AG, Colby TV, Dubois RM, Hansell DM, Wells AU. The prognostic significance of the histologic pattern of interstitial pneumonia in patients presenting with the clinical entity of cryptogenic fibrosing alveolitis. *Am J Respir Crit Care Med* 2000;162:2213–2217.
7. Travis WD, Matsui K, Moss JE, Ferrans VJ. Idiopathic nonspecific interstitial pneumonia: prognostic significance of cellular and fibrosing patterns: survival comparison with usual interstitial pneumonia and desquamative interstitial pneumonia. *Am J Surg Pathol* 2000;24:19–33.
8. Flaherty KR, Toews GB, Travis WD, Colby TV, Kazerooni EA, Gross BH, Jain A, Strawderman RL III, Paine R, Flint A, *et al.* Clinical significance of histological classification of idiopathic interstitial pneumonia. *Eur Respir J* 2002;19:275–283.
9. Flaherty KR, Travis WD, Colby TV, Toews GB, Kazerooni EA, Gross BH, Jain A, Strawderman RL, Flint A, Lynch JP, *et al.* Histopathologic variability in usual and nonspecific interstitial pneumonias. *Am J Respir Crit Care Med* 2001;164:1722–1727.
10. Flaherty KR, King TE Jr, Raghu G, Lynch JP III, Colby TV, Travis WD, Gross BH, Kazerooni EA, Toews GB, Long Q, *et al.* Idiopathic interstitial pneumonia: what is the effect of a multi-disciplinary approach to diagnosis? *Am J Respir Crit Care Med* 2004;170:904–910.
11. Glazer CS, Rose CS, Lynch DA. Clinical and radiologic manifestations of hypersensitivity pneumonitis. *J Thorac Imaging* 2002;17:261–272.
12. Lynch DA, Rose CS, Way D, King TE. Hypersensitivity pneumonitis: sensitivity of high-resolution CT in a population-based study. *AJR Am J Roentgenol* 1992;159:469–472.
13. Matar LD, McAdams HP, Sporn TA. Hypersensitivity pneumonitis. *AJR Am J Roentgenol* 2000;174:1061–1066.
14. Patel RA, Sellami D, Gotway MB, Golden JA, Webb WR. Hypersensitivity pneumonitis: patterns on high-resolution CT. *J Comput Assist Tomogr* 2000;24:965–970.
15. Remy-Jardin M, Remy J, Wallaert B, Muller NL. Subacute and chronic bird breeder hypersensitivity pneumonitis: sequential evaluation with CT and correlation with lung function tests and bronchoalveolar lavage. *Radiology* 1993;189:111–118.
16. Monaghan H, Wells AU, Colby TV, du Bois RM, Hansell DM, Nicholson AG. Prognostic implications of histologic patterns in multiple surgical lung biopsies from patients with idiopathic interstitial pneumonias. *Chest* 2004;125:522–526.
17. Jegal Y, Kim DS, Shim TS, Lim CM, Lee SD, Koh Y, Kim WS, Kim WD, Lee JS, Travis WD, *et al.* Physiology is a stronger predictor of survival than pathology in fibrotic interstitial pneumonia. *Am J Respir Crit Care Med* 2005;171:639–644.
18. Do KH, Lee JS, Colby TV, Kitaichi M, Kim DS. Nonspecific interstitial pneumonia versus usual interstitial pneumonia: differences in the density histogram of high-resolution CT. *J Comput Assist Tomogr* 2005;29:544–548.
19. Johkoh T, Muller NL, Colby TV, Ichikado K, Taniguchi H, Kondoh Y, Fujimoto K, Kinoshita M, Arakawa H, Yamada H, *et al.* Nonspecific interstitial pneumonia: correlation between thin-section CT findings and pathologic subgroups in 55 patients. *Radiology* 2002;225:199–204.
20. Park JS, Lee KS, Kim JS, Park CS, Suh YL, Choi DL, Kim KJ. Nonspecific interstitial pneumonia with fibrosis: radiographic and CT findings in seven patients. *Radiology* 1995;195:645–648.
21. Nagai S, Kitaichi M, Itoh H, Nishimura K, Izumi T, Colby TV. Idiopathic nonspecific interstitial pneumonia/fibrosis: comparison with idiopathic pulmonary fibrosis and BOOP *Eur Respir J* 1998;12:1010–1019. [Published erratum appears in *Eur Respir J* 1999;13:171.]
22. Remy-Jardin M, Remy J, Gosselin B, Becette V, Edme JL. Lung parenchymal changes secondary to cigarette smoking: pathologic-CT correlations. *Radiology* 1993;186:643–651.
23. Keller CA, Naunheim KS, Osterloh J, Espiritu J, McDonald JW, Ramos RR. Histopathologic diagnosis made in lung tissue resected from patients with severe emphysema undergoing lung volume reduction surgery. *Chest* 1997;111:941–947.
24. Craig PJ, Wells AU, Doffman S, Rassl D, Colby TV, Hansell DM, du Bois RM, Nicholson AG. Desquamative interstitial pneumonia, respiratory bronchiolitis and their relationship to smoking. *Histopathology* 2004;45:275–282.
25. Fraig M, Shreesha U, Savici D, Katzenstein AL. Respiratory bronchiolitis: a clinicopathologic study in current smokers, ex-smokers, and never-smokers. *Am J Surg Pathol* 2002;26:647–653.

26. Myers JL, Veal CF Jr, Shin MS, Katzenstein AL. Respiratory bronchiolitis causing interstitial lung disease: a clinicopathologic study of six cases. *Am Rev Respir Dis* 1987;135:880–884.
27. Fukuoka J, Franks TJ, Colby TV, Flaherty KR, Galvin JR, Hayden D, Gochuico BR, Kazerooni EA, Martinez F, Travis WD. Peribronchiolar metaplasia: a common histologic lesion in diffuse lung disease and a rare cause of interstitial lung disease: clinicopathologic features of 15 cases. *Am J Surg Pathol* 2005;29:948–954.
28. Churg A, Myers J, Suarez T, Gaxiola M, Estrada A, Mejia M, Selman M. Airway-centered interstitial fibrosis: a distinct form of aggressive diffuse lung disease. *Am J Surg Pathol* 2004;28:62–68.
29. Yousem SA, Dacic S. Idiopathic bronchiolocentric interstitial pneumonia. *Mod Pathol* 2002;15:1148–1153.
30. Elliot TL, Lynch DA, Newell JD Jr, Cool C, Tuder R, Markopoulou K, Veve R, Brown KK. High-resolution computed tomography features of nonspecific interstitial pneumonia and usual interstitial pneumonia. *J Comput Assist Tomogr* 2005;29:339–345.
31. Hartman TE, Swensen SJ, Hansell DM, Colby TV, Myers JL, Tazelaar HD, Nicholson AG, Wells AU, Ryu JH, Midthun DE, *et al.* Nonspecific interstitial pneumonia: variable appearance at high-resolution chest CT. *Radiology* 2000;217:701–705.
32. Kim EY, Lee KS, Chung MP, Kwon OJ, Kim TS, Hwang JH. Nonspecific interstitial pneumonia with fibrosis: serial high-resolution CT findings with functional correlation. *AJR Am J Roentgenol* 1999;173: 949–953.
33. Kim TS, Lee KS, Chung MP, Han J, Park JS, Hwang JH, Kwon OJ, Rhee CH. Nonspecific interstitial pneumonia with fibrosis: high-resolution CT and pathologic findings. *AJR Am J Roentgenol* 1998; 171:1645–1650.
34. Tsubamoto M, Muller NL, Johkoh T, Ichikado K, Taniguchi H, Kondoh Y, Fujimoto K, Arakawa H, Koyama M, Kozuka T, *et al.* Pathologic subgroups of nonspecific interstitial pneumonia: differential diagnosis from other idiopathic interstitial pneumonias on high-resolution computed tomography. *J Comput Assist Tomogr* 2005;29:793–800.
35. Fujita J, Yoshinouchi T, Ohtsuki Y, Tokuda M, Yang Y, Yamadori I, Bandoh S, Ishida T, Takahara J, Ueda R. Non-specific interstitial pneumonia as pulmonary involvement of systemic sclerosis. *Ann Rheum Dis* 2001;60:281–283.
36. Kim DS, Yoo B, Lee JS, Kim EK, Lim CM, Lee SD, Koh Y, Kim WS, Kim WD, Colby TV, *et al.* The major histopathologic pattern of pulmonary fibrosis in scleroderma is nonspecific interstitial pneumonia. *Sarcoidosis Vasc Diffuse Lung Dis* 2002;19:121–127.
37. Bouros D, Wells AU, Nicholson AG, Colby TV, Polychronopoulos V, Pantelidis P, Haslam PL, Vassilakis DA, Black CM, du Bois RM. Histopathologic subsets of fibrosing alveolitis in patients with systemic sclerosis and their relationship to outcome. *Am J Respir Crit Care Med* 2002;165:1581–1586.
38. Desai SR, Veeraraghavan S, Hansell DM, Nikolakopolou A, Goh NS, Nicholson AG, Colby TV, Denton CP, Black CM, du Bois RM, *et al.* CT features of lung disease in patients with systemic sclerosis: comparison with idiopathic pulmonary fibrosis and nonspecific interstitial pneumonia. *Radiology* 2004;232:560–567.
39. Nicholson AG, Colby TV, Wells AU. Histopathological approach to patterns of interstitial pneumonia in patient with connective tissue disorders. *Sarcoidosis Vasc Diffuse Lung Dis* 2002;19:10–17.
40. Tansey D, Wells AU, Colby TV, Ip S, Nikolakoupolou A, du Bois RM, Hansell DM, Nicholson AG. Variations in histological patterns of interstitial pneumonia between connective tissue disorders and their relationship to prognosis. *Histopathology* 2004;44:585–596.
41. Homma Y, Ohtsuka Y, Tanimura K, Kusaka H, Munakata M, Kawakami Y, Ogasawara H. Can interstitial pneumonia as the sole presentation of collagen vascular diseases be differentiated from idiopathic interstitial pneumonia? *Respiration* 1995;62:248–251.
42. Flieder DB, Travis WD. Pathologic characteristics of drug-induced lung disease. *Clin Chest Med* 2004;25:37–45.
43. Pesenti S, Lauque D, Daste G, Boulay V, Pujazon MC, Carles P. Diffuse infiltrative lung disease associated with flecainide: report of two cases. *Respiration* 2002;69:182–185.
44. Rossi SE, Erasmus JJ, McAdams HP, Sporn TA, Goodman PC. Pulmonary drug toxicity: radiologic and pathologic manifestations. *Radiographics* 2000;20:1245–1259.
45. Chibbar R, Shih F, Baga M, Torlakovic E, Ramlall K, Skomro R, Cockcroft DW, Lemire EG. Nonspecific interstitial pneumonia and usual interstitial pneumonia with mutation in surfactant protein C in familial pulmonary fibrosis. *Mod Pathol* 2004;17:973–980.
46. Kim HB, Lee SY, Kim JH, Jang JY, Huh J, Park SJ, Hong SJ. Familial interstitial lung disease in two young Korean sisters. *J Korean Med Sci* 2005;20:1066–1069.
47. Thomas AQ, Lane K, Phillips J III, Prince M, Markin C, Speer M, Schwartz DA, Gaddipati R, Marney A, Johnson J, *et al.* Heterozygosity for a surfactant protein C gene mutation associated with usual interstitial pneumonitis and cellular nonspecific interstitial pneumonitis in one kindred. *Am J Respir Crit Care Med* 2002;165:1322–1328.
48. Churg A, Muller NL, Flint J, Wright JL. Chronic hypersensitivity pneumonitis. *Am J Surg Pathol* 2006;30:201–208.
49. Vourlekis JS, Schwarz MI, Cool CD, Tuder RM, King TE, Brown KK. Nonspecific interstitial pneumonitis as the sole histologic expression of hypersensitivity pneumonitis. *Am J Med* 2002;112:490–493.